FRACTURES AND PHYSICAL THERAPY MANAGEMENT

HELEN BUCHANAN, SPT

PHYT 734 Fall 2019

Adapted from previous presentation by Jonathan Valbuena, PT

OBJECTIVES

1. Understand an overview of bone tissue, risk factors for fracture, and general healing times.
2. Be able to describe various fractures by using specific terminology based on MOI, classification, location, fracture pattern, and position/alignment.
3. Appreciate signs/symptoms of possible fractures and the Ottawa Rules for Knee and Ankle suspected fractures.
4. Be able to describe the Salter-Harris Classification system for epiphyseal plate injuries.
5. Be able to apply principles of fracture management for periods of immobilization and post-immobilization in clinical practice.

BRIEF OVERVIEW OF BONE[1]

- Composition
  - Fiber = Type I collagen
  - Ground Substance = GAGs, hyaluronic acid, calcium salts
  - Cells = Osteoblasts and Osteoclasts
- Types of Bone
  - Cortical
  - Cancellous

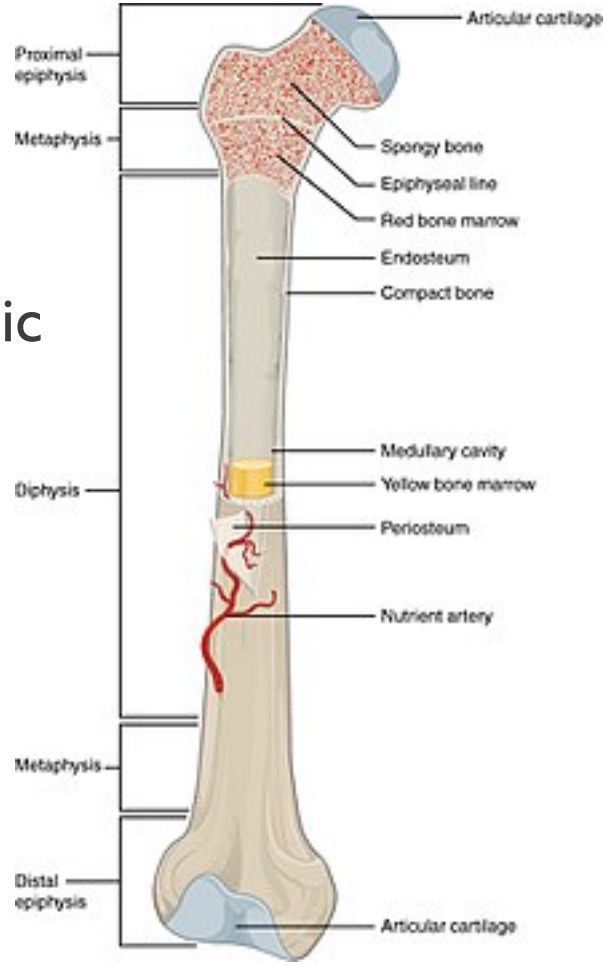

Image from OpenStax[A]

HOW DO BONES BREAK?

- Trauma
- Fatigue or Stress
- Pathology

Image from Getty Images[B]

BONE AND STRESS-STRAIN

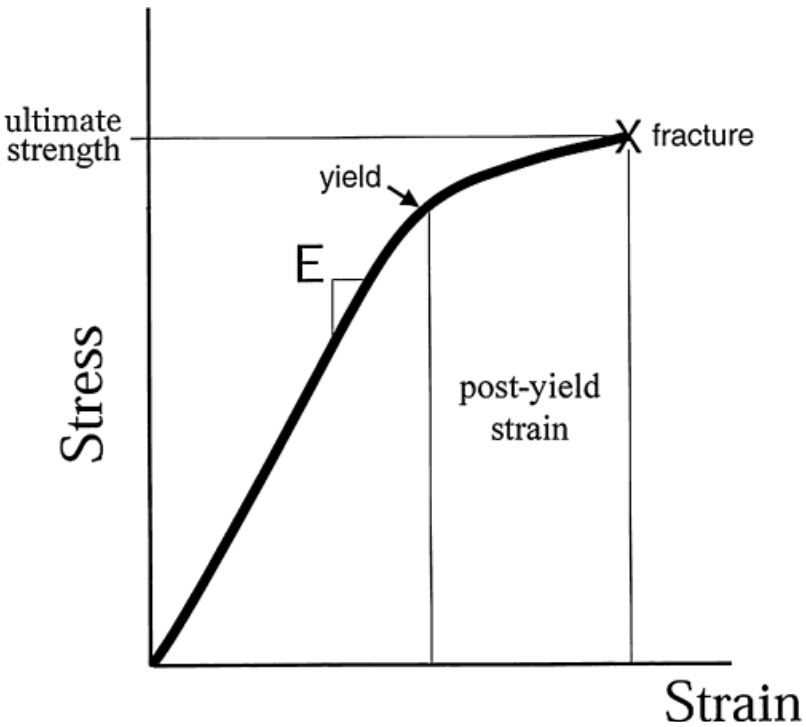

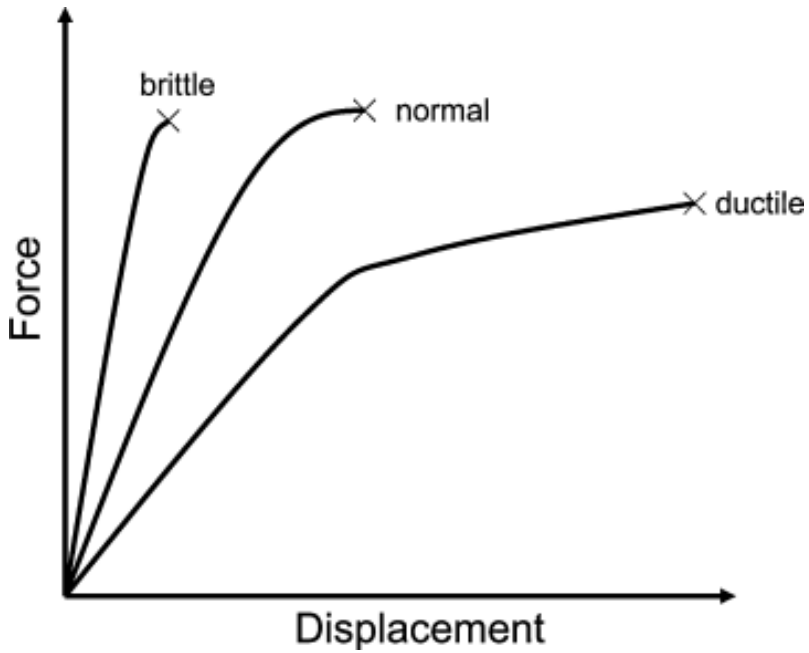

Figures from Turner[C]

RISK FACTORS FOR FRACTURE[2]

- Sudden impact
  - Ex: trauma, accidents, assault
- Osteoporosis
  - Women > Men
- History of falls
  - Especially with increased age, low BMI, and low levels of PA
- Repetitive stress
  - Repeated microtrauma
- Pathology
  - Abnormal fragile bone from neoplastic, poor health, or disease condition

ASSOCIATED FRACTURE DAMAGE

- Edema
- Ecchymosis
- Hemorrhage
- Ruptured tendons/ligaments
- Severed nerves
- Damaged blood vessels
- Injury to organs and muscle/soft tissues
- Joint dislocation

BUT *HOW* DID A BONE BREAK?



Image from Barefoot Meds[D]

MECHANISM OF INJURY[1]

- Speed of Loading
  - ↑ Speed of loading = ↑ ultimate strength and stiffness of bone
    - ↑ Energy release at failure
      - = More potential for soft tissue and other associated damage

MECHANISM OF INJURY[1]

- Frequency of Loading
  - ↑ Frequency associated with ↓ ultimate strength of tissue
    - = Cumulative microtrauma leads to failure

DEFINING AND DESCRIBING FRACTURES

- Classification
- Location
- Fracture Patterns/Types
- Position/Alignment

IMAGING ABC's

- A = alignment
- B = bones
- C = cartilage space
- s = soft tissue

Image from Radiopaedia[E]

CLASSIFICATION

- Open
- Closed

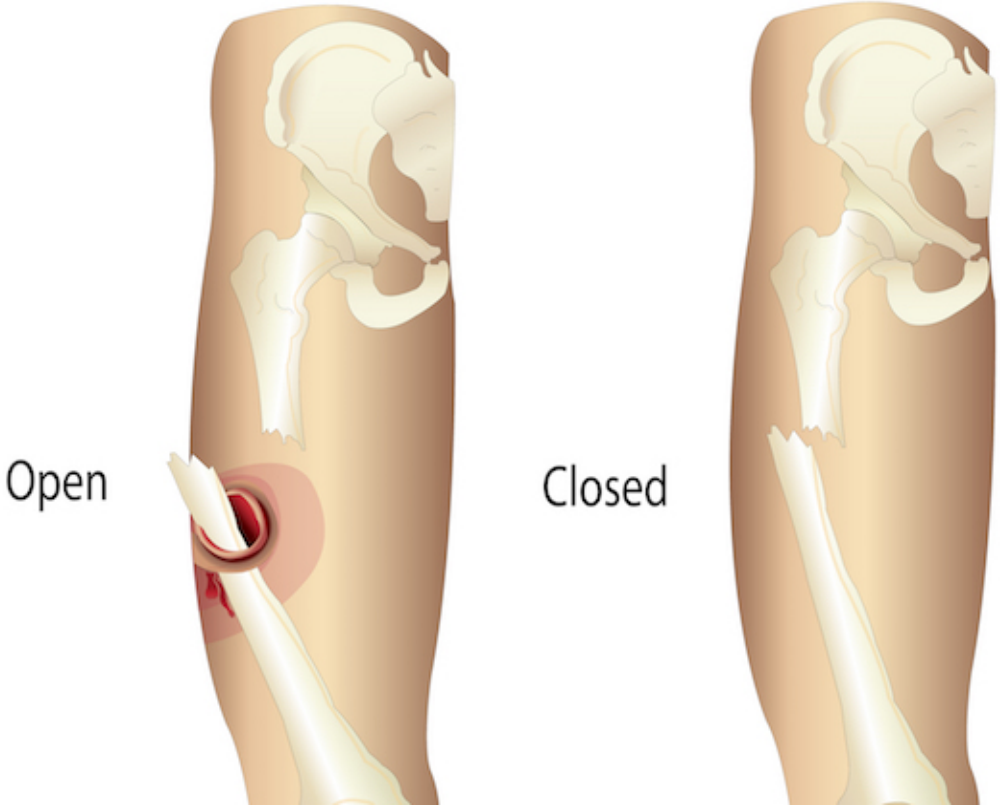

Image from Lex Medicus[F]

LOCATION

- Specific bone
- Location within a bone
  - Proximal
  - Distal

FRACTURE PATTERNS/ TYPES

- Transverse
- Linear
- Oblique
- Spiral
- Comminuted
- Avulsion
- Greenstick
- Torus/Buckle
- Stress
- Pathologic

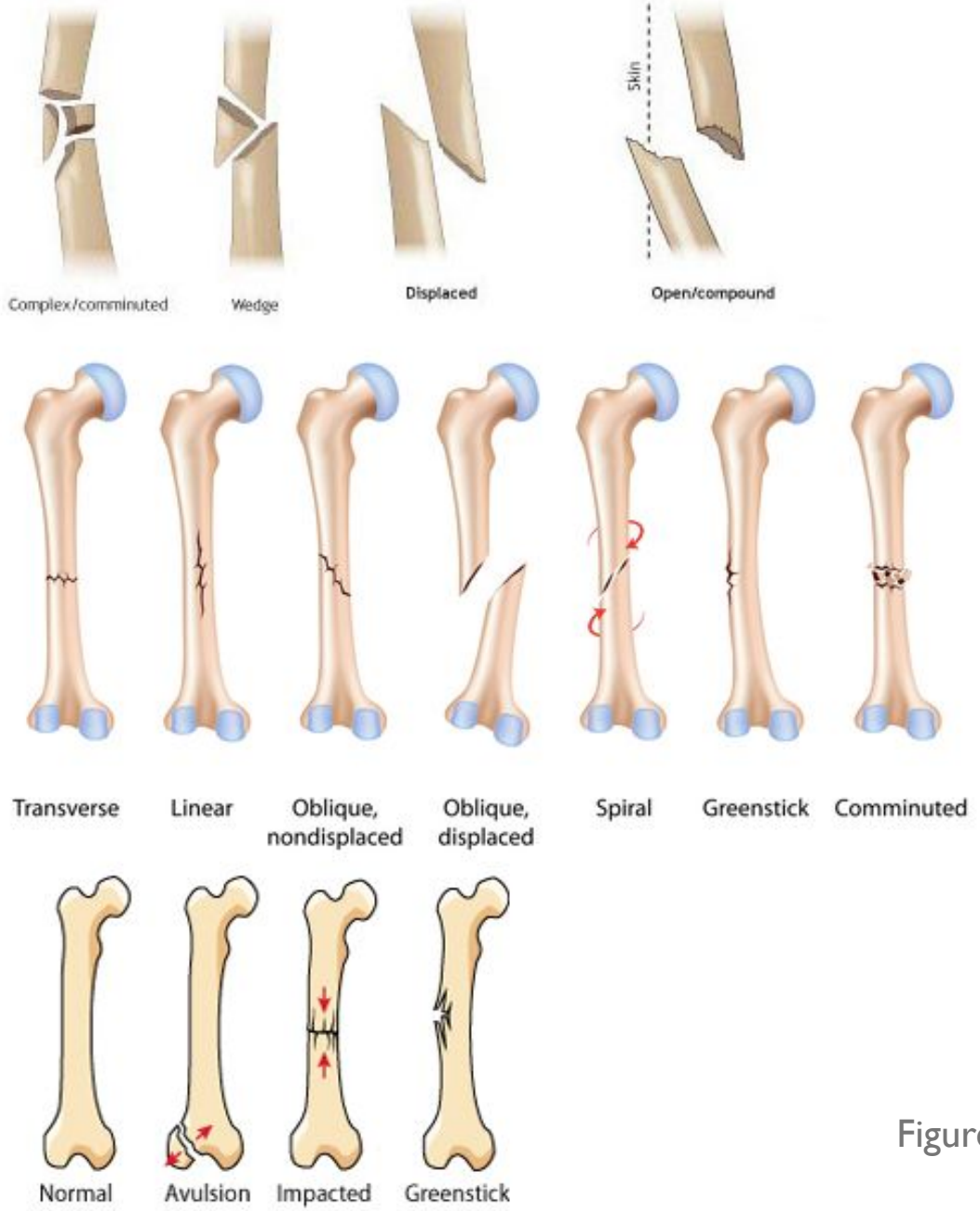

Figure from Dream Life[G]

POSITION AND ALIGNMENT

- Non-displaced
- Superior/Inferior displacement
- Anterior/Posterior displacement
- Medial/Lateral displacement
- Distracted
- Rotation

POSITION AND ALIGNMENT

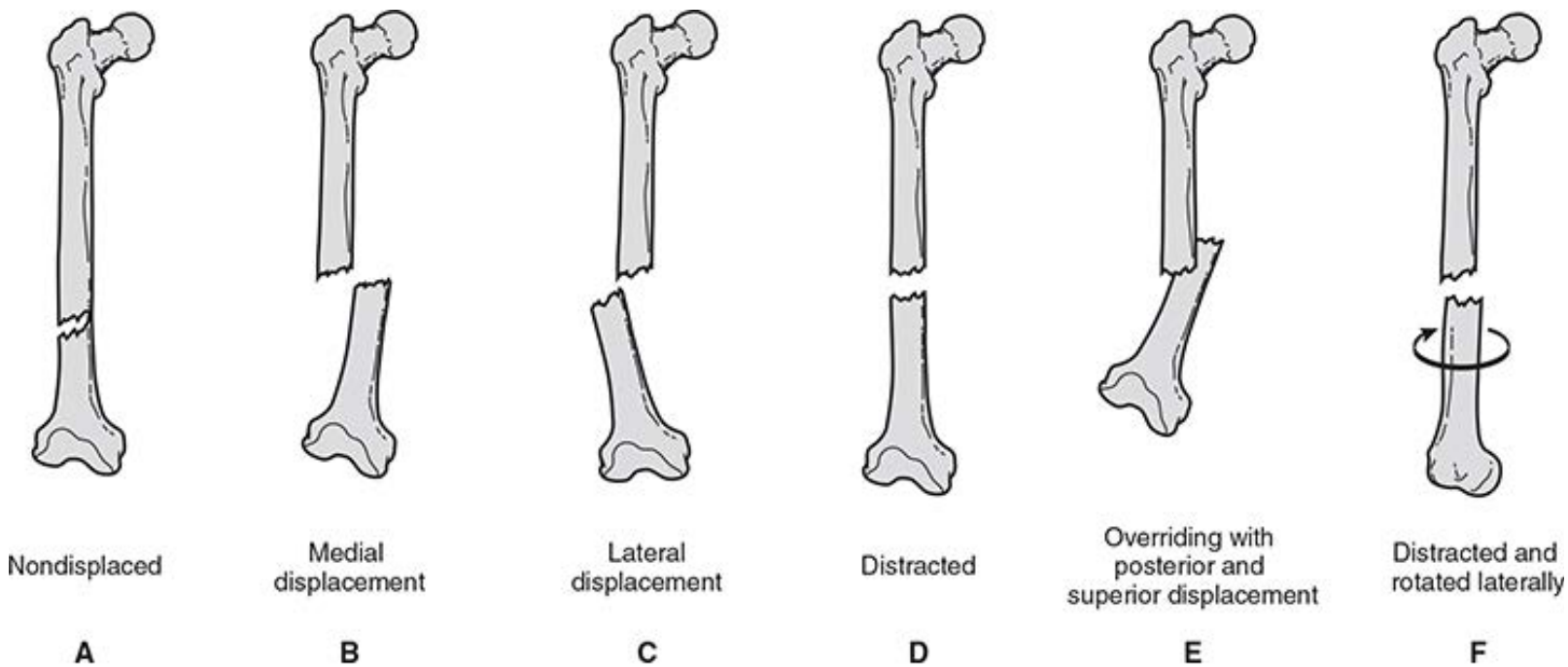

Source: Lynn N. McKinnis: *Fundamentals of Musculoskeletal Imaging*, 4th Edition: www.FADavisPTCollection.com

Image from Kisner et al[2]

HOW TO PUT IT ALL TOGETHER

- Convention description:
  - Distal segment position in relation to proximal segment
  - Angulation named by direction of angle apex
- Describe by classification, location, fracture line, and position/alignment

NAME THAT FRACTURE!

Images from Radiopaedia[H]

NAME THAT FRACTURE!

Images from Radiopaedia[1]

AP view

Lateral view

NAME THAT FRACTURE!

Images from Jon Hackel

PA view

Lateral view

NAME THAT FRACTURE!

Images from Radiopaedia[K]

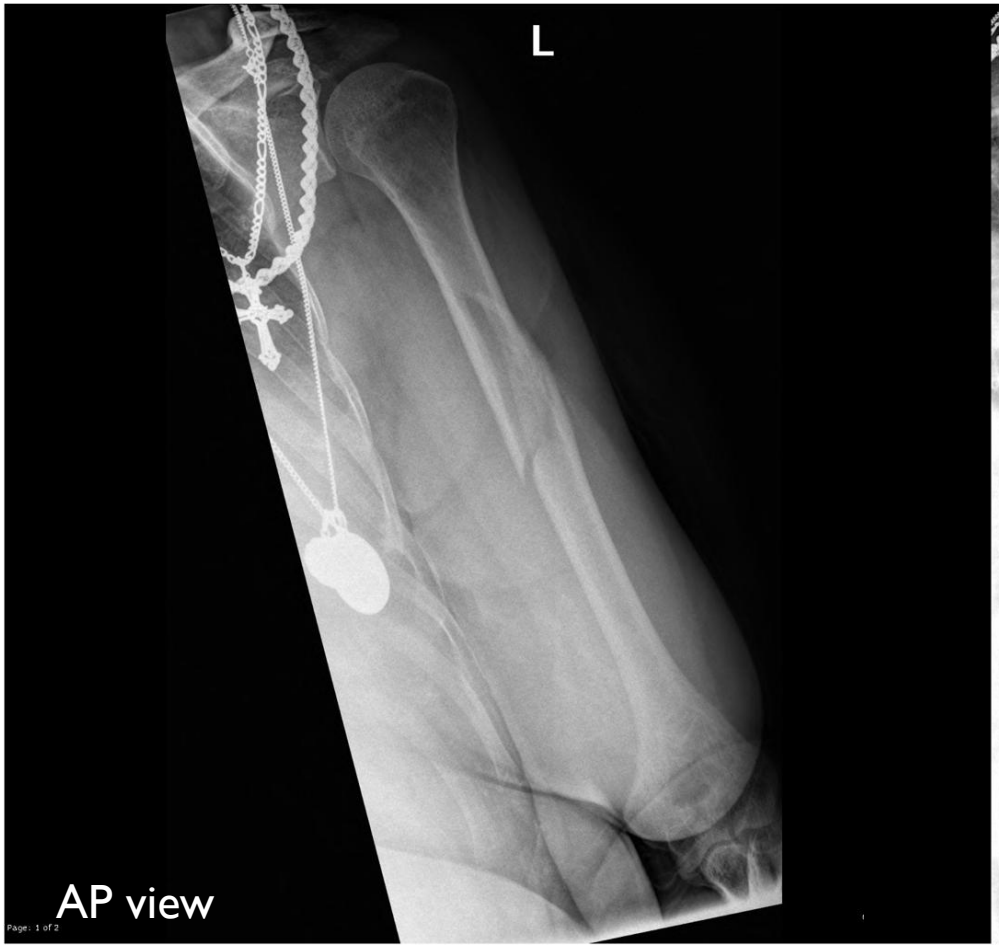

WHO NEEDS A BREAK…?

CAUSES AND TYPES OF FRACTURES[2]

Table adapted from Kisner et al[2]

Force	Effect on Bone	Type of Fracture
Bending	Long bone bends causing failure on convex side of bend	Transverse or oblique fracture; Greenstick fracture in children
Twisting (torsional)	Spiral tension failure in long bone	Spiral fracture
Traction	Tension failure from pull of ligament or muscle	Avulsion fracture
Crushing (compression)	Usually in cancellous bone	Compression fracture, torus (buckle) fracture in children
Repetitive Microtrauma	Small crack in bone	Fatigue or stress fracture
Normal force on abnormal bone	E.g. osteoporosis, bony tumor, or other diseased bone	Pathological fracture

SIGNS/SYMPTOMS OF POSSIBLE FRACTURE[2]

- Swelling, deformity, or abnormal movement
  - *May or may not be visibly obvious!*
- Sharp, localized tenderness at site
- Localized pain aggravated by movement and/or weight-bearing
- Muscle guarding with PROM
- Decreased functional use of segment
- History of MOI
  - Fall, direct blow, twisting injury, or other trauma

OTTAWA ANKLE RULE

- A decision aid for excluding fractures of the ankle and midfoot
- Accurate predictor[3]
  - 36% reduction in unnecessary radiographs

OTTAWA ANKLE RULE

- Applies to ages 2 to 55
- Tender over posterior 6cm OR tip of the medial or lateral malleolus
- Base of 5th metatarsal
- Navicular
- Inability to bear weight (4 steps) BOTH immediately AND in the ED
  - Limping is OK

Adapted From:
Paul Mintken PT, DPT, OCS
Denise Stelzner PT, MBA
University of Colorado PT

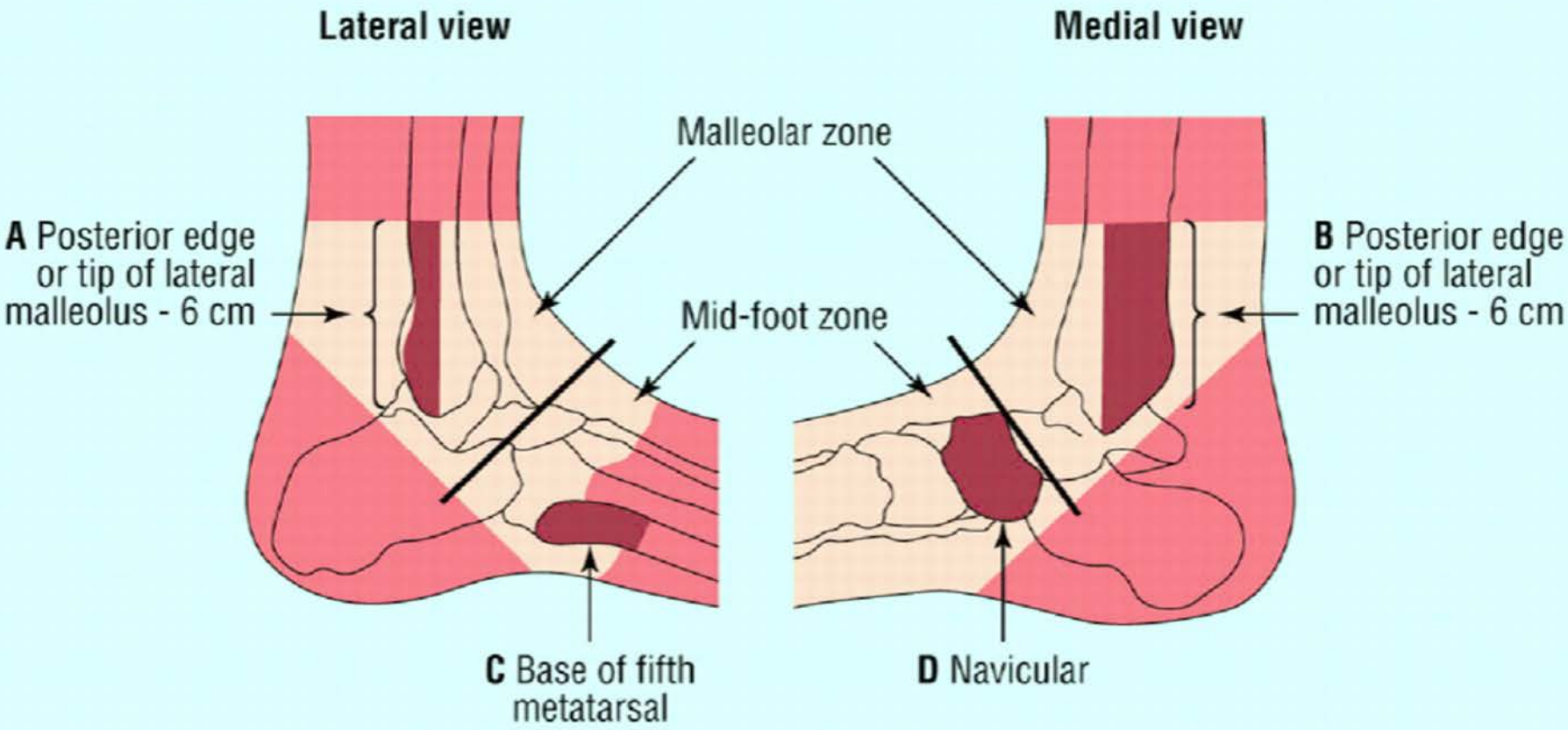

A series of ankle *x* ray films is required only if there is any pain in malleolar zone and any of these findings:

- Bone tenderness at **A**
- Bone tenderness at **B**
- Inability to bear weight both immediately and in emergency department

A series of ankle *x* ray films is required only if there is any pain in mid-foot zone and any of these findings:

- Bone tenderness at **C**
- Bone tenderness at **D**
- Inability to bear weight both immediately and in emergency department

OTTAWA KNEE RULE

- To determine whether a knee injury needs an X-ray
- Accurate predictor?
  - 26% reduction in unnecessary radiographs[4]

OTTAWA KNEE RULE[5]

- Radiographs indicated if any of the 5 are present:
  - Age 55 or older
  - Isolated tenderness over patella
  - Tenderness over fibular head
  - Unable to flex knee >90°
  - Unable to bear weight immediately or in the ED for 4 steps

EPIPHYSEAL PLATE = GROWTH PLATE

- Area of growth in long bone
- Between epiphysis and metaphysis of long bones

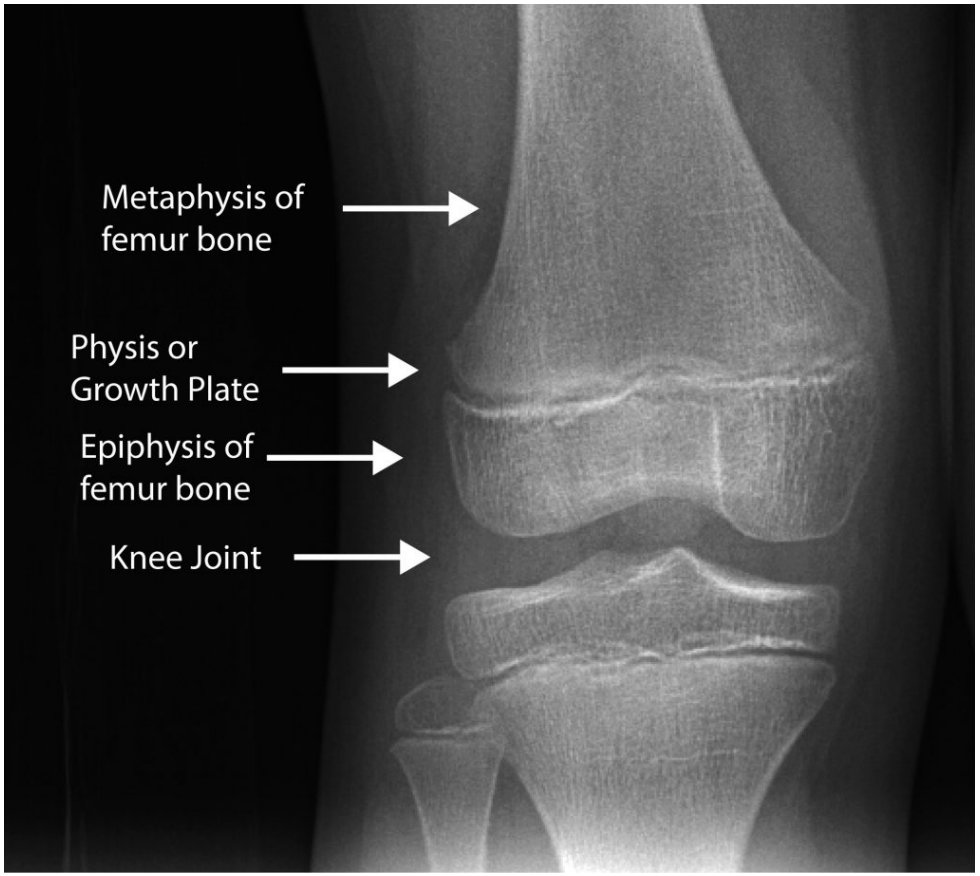

Image from LLRS[L]

SALTER-HARRIS FRACTURE CLASSIFICATION

- Specific to fractures at the epiphyseal plate
- 5 categories based on damage

Type I	Type II	Type III	Type IV	Type V
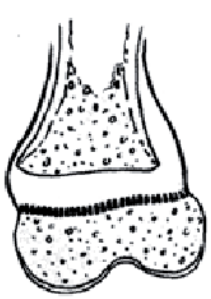	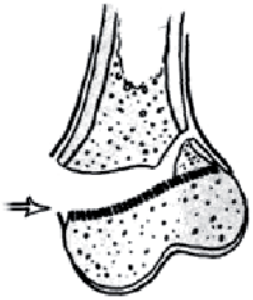	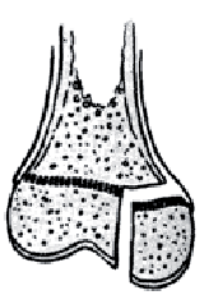		
A transverse fracture through the growth plate, sparing the epiphysis and metaphysis.	A fracture through the growth plate and the metaphysis, with its fragment adhering to the growth plate.	A fracture through the growth plate and the epiphysis.	A fracture through the growth plate, metaphysis, and epiphysis.	The growth plate is compressed, without any fracture of the epiphysis or the metaphysis.

Figure from Kuleta-Bosak et al[M]

SALTER-HARRIS TYPE I

- Shearing injury[1]
- Epiphysis is completely separated from metaphysis
- Rarely manipulated, requires immobilization
- Good prognosis

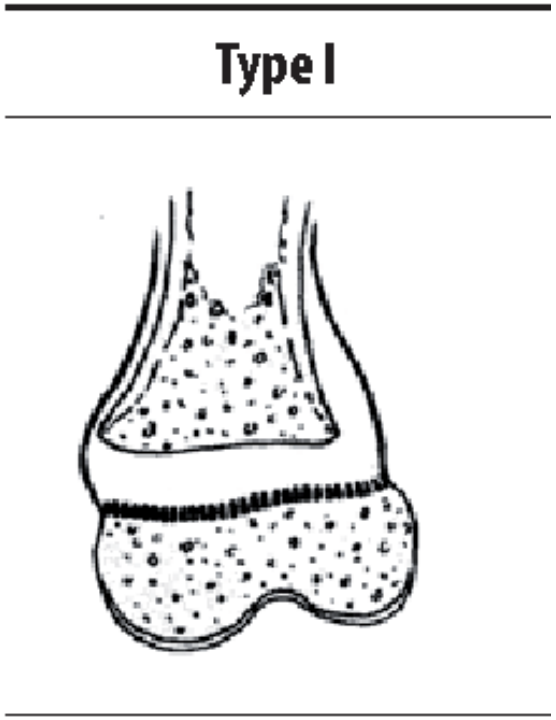

Figure from Kuleta-Bosak et al[M]

SALTER-HARRIS TYPE II

- Shearing and bending injury[1]
- Epiphysis and growth plate partially separated from metaphysis, fracture through part of metaphysis
- Most common
- Manipulated and immobilized
- Good prognosis

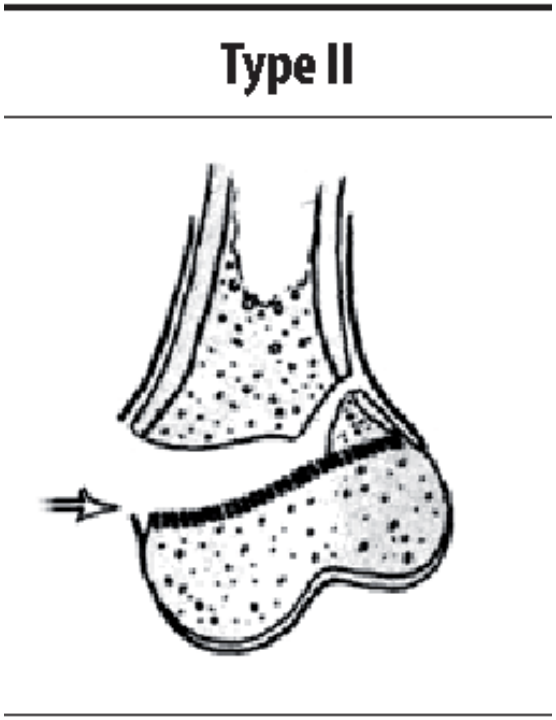

Figure from Kuleta-Bosak et al[M]

SALTER-HARRIS TYPE III

- Fracture through epiphysis, separates part of epiphysis and growth plate from metaphysis
- Rare
- Typically requires surgical reduction

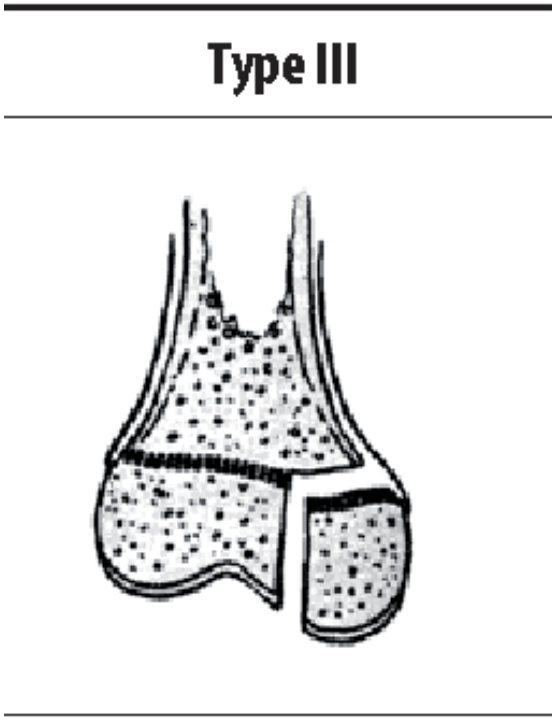

Figure from Kuleta-Bosak et al[M]

SALTER-HARRIS TYPE IV

- Fracture through epiphysis and into metaphysis crossing growth plate
- Surgery required
- Potential for premature closing of growth plate if not perfectly aligned

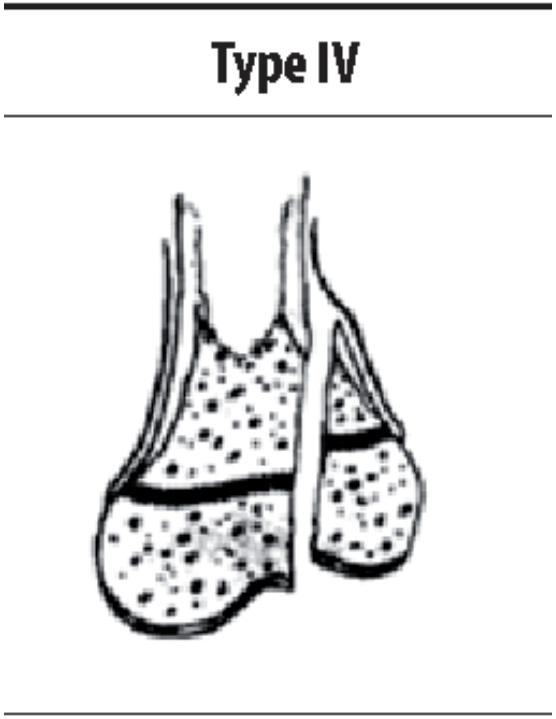

Figure from Kuleta-Bosak et al[M]

SALTER-HARRIS TYPE V

- Epiphysis crushed into metaphysis, crushing the growth plate
- Poor prognosis, stunted growth
- Difficult to diagnose, needs to be treated with NWB immediately[1]

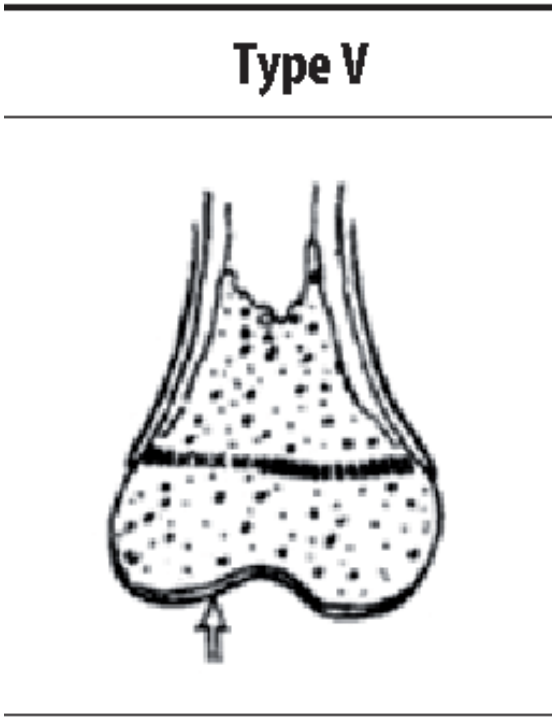

Figure from Kuleta-Bosak et al[M]

BONE GENERAL HEALING TIME[2]

- Varies with age, location and type of fracture, displacement, surgical involvement, soft tissue damage, and vascularity around the repair
  - Children = 4-6 weeks
  - Adolescents = 6-8 weeks
  - Adults = 10-18 weeks
- Smoking and NSAIDs negatively affect bone healing!

STAGES OF FRACTURE HEALING[6]

- Inflammatory
  - Begins immediately after bone injury with formation of fibrin clot or hematoma
- Repair
  - Begins a few days after bone injury
    - "soft callus" formation for 6 weeks
    - "hard callus" formation for 12 weeks
- Remodeling
  - Can continue for months or years after bone injury

POTENTIAL COMPLICATIONS[2]

- Swelling
- Fat embolism
- Skin ulceration, vascular compromise
- Nerve injury
- Infection
- Delayed union or Malunion
- Refracture
- Problems with fixation devices

PERIOD OF IMMOBILIZATION[2]

- Bone requires immobilization for healing
  - But connective tissue weakens, articular cartilage degrades, muscle atrophies, at risk for contracture, and slowed circulation
- Early "non-destructive" motion is ideal but usually not feasible unless an internal fixation device is present to stabilize

IMMOBILIZATION: PT MANAGEMENT[2]

- Be on alert for complications
- General exercises for uninvolved portions of the body to minimize soft tissue degradation
  - Especially important for bed rest with traction!
- If LE involved, educate in alternative modes of mobility within WBing limitations
  - Crutches, walker, WC – clinical judgment is key

EXTERNAL FIXATION



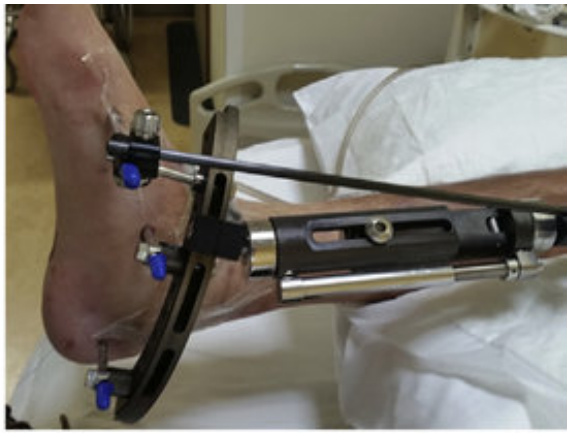


Images from Schepers T, Rammelt[N]

IMMOBILIZATION: PT SUMMARY[2]

Plan of Care	Intervention
1. Educate the patient	1. Teach functional adaptations and safe ambulation, bed mobility
2. Decrease effects of inflammation during acute period	2. Ice, elevation
3. Decrease effects of immobilization	3. Intermittent muscle setting, active ROM to joints above and below immobilized region
4. It patient is confined to bed, maintain ROM and strength in major muscle groups	4. ROM activities to all areas not immobilized, resistive exercises to major muscle groups not immobilized especially in preparation for future ambulation

POST-IMMOBILIZATION[2]

- Following immobilization, many impairments likely:
  - Decreased ROM, joint play, muscle flexibility
  - Muscle atrophy and poor endurance
  - Painful movement early on
  - Inelastic scar tissue?

POST-IMMOBILIZATION: PT MANAGEMENT[2]

- Consult physician for clinical vs. radiological healing expectations
- Match interventions to impairments
  - Joint mobilization
  - Muscle stretching, strengthening and endurance
    - PNF: proximal hold-relax and agonist-contraction
  - Functional activities
  - Scar tissue mobilization for soft tissue injuries

POST-IMMOBILIZATION: PT SUMMARY[2]

- Plan of Care
  1. Educate the patient
  2. Provide protection until radiologically healed
  3. Initiate active exercises
  4. Increase joint and soft tissue mobility
  5. Increase strength and muscle endurance
  6. Improve cardiorespiratory fitness

POST-IMMOBILIZATION: PT SUMMARY[2]

- Interventions
  1. Inform patient of:
     a. Limitations
     b. Home exercises/Reinforce protection
  2. PWB in LE injuries, non-stressful activities in UE injuries
  3. Active ROM, gentle multi-angle isometrics
  4. Joint play and muscle stretching
  5. Resistive and repetitive exercises as ROM increases
  6. Safe aerobic exercises that do not stress fracture site

ANY QUESTIONS?

Image from SNL©

REFERENCES

Original Presentation: Valbuena, J. Lower Extremity Fractures/TJR and Physical Therapy Management. October 22, 2018; Chapel Hill, NC.

1. Gross, M. Bone – Lectures I & II. Lecture presented as VoiceThread; created on July 11 and 13, 2008; Chapel Hill, NC.
2. Kisner C, Thorp JN, Holtgrefe K.. Joint, Connective Tissue, and Bone Disorders and Their Management: Fractures and Posttraumatic Immobilization. In: *Therapeutic Exercise Foundations and Techniques*. 7th ed. Philadelphia, PA: F.A. Davis Company; 2018:350-354.
3. Stiell IG, Greenberg GH, McKnight RD, et al. A study to develop clinical decision rules for the use of radiography in acute ankle injuries. *Ann Emerg Med* 1992 Apr;21(4):384-90. doi 10.1016/s0196-0644(05)82656-3.
4. Stiell IG, Wells GA, Hoag RH, Sivilotti ML, et al. Implementation of the Ottawa Knee Rule for the use of radiography in acute knee injuries. *JAMA* 1997 Dec 17;278(23):2075-9. doi 10.1001/jama.1997.03550230051036.
5. Bachman LM, Kolb E, Koller MT, et al. Accuracy of Ottawa ankle rules to exclude fractures of the ankle and mid-foot: systematic review. *Ann IntMed*.2004;140:1221-124 doi 10.1136/bmj.326.7368.417.
6. Stages of healing. Available at: https://elentra.healthsci.queensu.ca/assets/modules/msk_bonemorph_agg/66d64b9728004605842f/66d64b9728004605842f.htm. Accessed October 23, 2019.

IMAGES AND FIGURES

A. https://openstax.org/books/anatomy-and-physiology/pages/6-3-bone-structure

B. https://www.wsj.com/articles/SB10001424127887323296504578396832875546130

C. Turner CH. Bone strength: current concepts. *Ann N Y Acad Sci*. 2006;1068:429-446. doi:10.1196/annals.1346.039

D. https://barefootmeds.wordpress.com/2012/10/01/studying-skeleton/

E. https://radiopaedia.org/cases/radial-neck-fracture-and-sail-sign?lang=us

F. ttp://pathologies.lexmedicus.com.au/pathologies/femur-shaft-fracture

G. Dream Life for Nurses. Available at: https://www.pinterest.com/pin/812266482762856540/?nic=1.

H. https://radiopaedia.org/cases/tibia-fracture-importance-of-2-views?lang=us

I. https://radiopaedia.org/cases/oblique-tibial-fracture?lang=us

J. Guide Radiology Forearm Answers from Jon Hacke

K. https://radiopaedia.org/cases/humeral-fracture-spiral-wedge-midshaft?lang=us

L. Limb Lengthening and Reconstruction Society. Available at: https://llrs.org/information-for-patients/specific-conditions/growth-plate-arrest/

M. Kuleta-Bosak E, Bożek P, Kluczewska E, Tomaszewski R, Machnik-Broncel J. Salter-Harris type II fracture of the femoral bone in a 14-year-old boy – case report. *undefined*. 2010

N. Schepers T, Rammelt S. Complex foot injury: early and definite management. *Foot Ankle Clin* 2017;22(1):193-213. doi:10.1016/j.fcl.2016.09.014.

O. SNL Haunted Elevator. Available at: https://www.youtube.com/watch?v=rS00xWnqwvI