Alex Smith

The Multiple Etiologies of Anterior Hip Pain

Introduction

Anterior hip and groin pain is a very common complaint with many conceivable causes.[1] Unfortunately, accurate diagnosis is often difficult due to the many structures of the hip that often produce similar pain symptoms.[1,2] Likewise, many of these pain producers come from deep within the hip and are unable to be palpated upon examination.[2] Hip pathology may also refer pain to other areas and similarly, pathology in other areas may refer pain to the hip.[1] Although accurate diagnosis is difficult, distinguishing between the various causes of hip and groin pain is incredibly important for providing correct and effective treatment.[2] This research paper will review the multiple etiologies of hip pain, specifically femoroacetabular impingement, acetabular labral tears, athletic pubalgia, adductor strains, and iliopsoas-related injuries, along with specific evaluative tools and various treatments for these conditions.

Femoroacetabular Impingement:

Femoroacetabular impingement (FAI) is a common cause of hip pain, especially in active young adults.[3] The etiology of FAI may be the result of a combination of factors, such as environmental factors and developmental abnormalities.[4] Developmental abnormalities may include, but are not limited to, coxa profunda, acetabular retroversion and protrusio acetabuli.[4] Irrespective of the etiology, the resultant morphological abnormalities in the acetabulum and/or proximal femur result in abnormal contact of surfaces during hip flexion.[4,5] Thus, this abnormal contact causes increased pressure and friction between the ball and socket of the hip joint resulting in pain, decreased range of motion (ROM) and progressive hip dysfunction.[4]

The anterosuperior rim of the acetabulum is the most common location for FAI.[4] However, Ganz et al.[6] have classified FAI into two major categories: cam-type impingements and pincer-type impingements (see figure 1). Cam impingements are most common in physically active young men and are characterized by an aspherical femoral head with a resultant loss of femoral head-neck concavity.[4] Ganz et al.[6] state, "cam impingement is caused by jamming of an abnormal femoral head with increasing radius into the acetabulum during forceful motion, especially flexion." It is common for cysts to develop in the femoral head-neck junction early in the disease process; however, the labrum remains initially unaffected.[4] Pincer impingements are most often seen in active middle-aged women and are generally the result of an acetabular abnormality, specifically coxa profunda (deepening of the acetabular socket) or acetabular retroversion (anterior overgrowth of the acetabulum).[4,6,7] Unlike with cam impingements, the labrum is often the first structure affected in pincer impingements, often resulting in early labral tears.[4] Similarly, women with pincer impingements often report more severe pain than men with cam impingements.[4] Regardless of the type of impingement, it is evident that FAI is a predisposing factor to idiopathic arthritis.[6]

Upon clinical evaluation, an insidious onset of deep groin pain is the most common complaint in individuals with FAI; however, patients may also complain of buttocks or lateral hip pain that is worsened by hip flexion and any prolonged sitting or standing.[4,5] Dooley[8] suggests that individuals often identify the location of pain using the C Sign (see figure 2), in which affected individuals grasp their lateral hip, superior to the greater trochanter, between their thumb and index finger. Clohisy et al.[5] found pain to be activity-related in 71% of FAI cases, with walking, running, and pivoting proving to be

most difficult. A patient's gait pattern is generally antalgic with presence of gluteus medius weakness, as indicated by a positive Trendelenburg test (see figure 3).[8] Labral tears are common, especially in pincer impingements; thus, symptoms of locking and catching may be apparent.[4] Likewise, there will be major active and passive ROM limitations in hip flexion and internal rotation when the hip is in 90˚ of flexion [4,5,9] A positive anterior impingement test (see figure 4) is highly sensitive for FAI and is demonstrated in 90% of affected individuals.[8] The impingement test is considered positive if sudden pain is elicited when the hip is adducted and internally rotated while the hip and knee are flexed to 90˚.[8] A study by Clohisy et al.[5] found that in patients with FAI, 98.7% demonstrate a positive FABER's/Patrick's test while 88.6% demonstrate a positive anterior impingement test. The Drehmann Sign (see figure 5), compulsory hip abduction and external rotation with hip flexion, is often positive in individuals with FAI.[10] Early detection and intervention of FAI is key because treatment may prolong the onset of osteoarthritis.[4] If FAI is suspected after careful and thorough examination, anteroposterior (AP) and lateral X-rays are required to confirm the diagnosis.[1]

Conservative treatment for FAI should be attempted initially.[4] This treatment includes nonsteroidal anti-inflammatory medication, modification of activity and reduction in levels of sports-specific activity that put excessive demand on the hip. Physical therapy is a discipline that should be utilized in the treatment process; however it is imperative that physical therapists avoid passive ROM of the hip as this can exacerbate symptoms.[4] Core strengthening and proprioceptive training should be the emphasis of physical therapy and this can be done using wobble boards, physio balls,

and roller boards. If conservative measures fail, surgical management should be considered via femoroacetabular osteoplasty or hip arthoscopy.[4]

Acetabular Labral Tears

Besides providing increased joint lubrication, the labrum is also a hip joint stabilizer that deepens the acetabulum by approximately 21% while increasing the surface area of the acetabulum by approximately 28%.[1] Labral tears decrease the contact area across the joint thus increasing stress and destabilizing the joint. There are four types of labral tears: radial flap, radial fibrillated, longitudinal peripheral, and abnormally mobile.[11] The most common type is the radial flap tear, occurring over the anterosuperior part of the inner aspect of the labrum.[11]

As mentioned previously, labral tears often occur in conjunction with FAI; however they can also be the result of dysplasia, capsular laxity, traumatic injury, and chondral lesions.[4,11] Similar to FAI, the most common complaint is anterior hip or groin pain, with the prevalence of labral tears occurring in 22-55% of patients with hip or groin pain.[1] Approximately 96-100% of patients with an arthroscopically recognized labral tear will complain of anterior hip or groin pain.[11] Although less common, pain may occur in the buttocks region and is more indicative of a posterior labral tear.[1] Individuals participating in athletic activities that require repetitive pivoting or hip flexion are at increased risk of labral tears.[12] The majority of patients report a gradual onset of symptoms that worsen with activity, prolonged sitting and walking.[12] Other symptoms include night pain, instability, clicking, locking, stiffness, giving way, decreased muscle strength and postural dysfunction.[1,13] Also, patients with labral tears will demonstrate a slight antalgic gait with a positive Trendelenburg sign.[10]

Physical examination tests will be important clinical tools for assessing labral tears. The impingement test, quadrant test, modified Thomas test, and Fitzgerald test have generally been used to assess for labral tears.[13] However, a systematic review by Burgess et al.[13] found the impingement test and the Fitzgerald test (see figure 6) to be the most sensitive physical tests for labral tears, as sensitivity values ranged from 75% to 98%, respectively.[13] Magnetic resonance arthrography (MRA) is the most specific and sensitive diagnostic imaging method for detecting acetabular labral tears.[12,13]

Conservative treatment for acetabular labral tears should be attempted initially with the primary focus on activity modification, NSAIDs and physical therapy.[12] Physical therapy should concentrate on realignment of the hip joint along with avoidance of excess forces across the anterior aspect of the hip.[12] Modification of activities include, 1) avoid sitting with the knees crossed or lower than the hips, 2) avoidance of excessive hip hyperextension when walking, and 3) avoidance of weight training of hamstring or quadriceps muscles.[12] Likewise, loaded hip rotation should be avoided.[12] Lewis et al.[14] state, "the appropriate intervention should focus on reducing anteriorly directed forces on the hip by addressing the patterns of recruitment of muscles that control hip motion, by correcting the movement patterns during exercises such as hip extension and during gait, and by instruction in the avoidance of pivoting motions in which the acetabulum rotates on the femur, particularly under load." If conservative measures fail, arthroscopic (labral repair or debridement) or open (surgical dislocation or osteoplasty) surgery may be attempted.[14]

Athletic Pubalgia

Another cause of anterior hip/groin pain is athletic pubalgia, also called sports hernia. Farber et al.[15] state, "The pathologic entity known as sports hernia is an occult hernia caused by weakness or tear of the posterior inguinal wall, without a clinically recognizable hernia, that leads to a condition of chronic groin pain." Likewise, it can also be caused by a shearing across the pubic symphysis from concurrent hyperextension of the trunk and hyper-abduction of the femur.[12] Thus, individuals with great muscle imbalance between the abdominals and the thigh muscles may be at greater risk for increased shear across the pubic symphysis and resultant athletic pubalgia.[12]

This condition occurs almost entirely in men and is common among athletes participating in sports that require a great deal of twisting and turning.[12,16] Lovell[17] found that in athletes with chronic groin pain, athletic pubalgia was the culprit in 50% of the cases. It generally manifests as insidious deep unilateral inguinal pain that is exacerbated by activity and relieved with rest. It often radiates to the adductors, perineum, rectal or testicular areas.[12,16] Although there is tenderness to palpation over the pubic tubercle and inguinal region, there is no detectable hernia present.[12,15] There is generally pain with sudden movement, thus the Valsalva technique is an important clinical tool for diagnosing athletic pubalgia.[12,15] Similarly, pain with resisted sit ups and resisted hip adduction will often be found in individuals with this condition.[12,15] Diagnostic imaging will often appear normal for individuals with this condition, however it is important to perform these tests to eliminate alternative diagnoses (e.g. avulsion fractures, adductor-related strains, stress fractures, osteitis pubis).[12,18]

Similar to FAI and labral tears, athletic pubalgia is also treated initially with conservative treatment such as rest, NSAIDs, heat or ice modalities, deep tissue massage, and physical therapy.[15] Physical therapy should focus on restoring normal balance of the abdominal, hip and pelvic muscles.[15] The rehabilitation protocol by Larson and Lohnes is suggested for athletes with athletic pubalgia.[15] This eight week protocol consists of four, two-week phases: 1) massage and stretching, 2) core strengthening, 3) return to functional activity, 4) return to sport-specific activity.[15] Unfortunately, most sports hernias do not respond to conservative measures thus surgery should be considered if symptoms do not improve after six to eight weeks of conservative treatment.[15]

Adductor Longus Strain:

The adductor longus originates at the superior pubic ramus and inserts along the middle third of the linea aspera of the femur.[19] The action of the adductor longus is hip abduction and hip flexion; as a group, the adductors act in conjunction with the lower abdominal muscles to stabilize the pelvis during lower extremity movement.[12] Due to its anatomical location and muscle action, adductor longus strains are often associated with groin pain, especially among athletes.[12,19] Individuals with decreased hip ROM, adductor weakness and adductor-abductor imbalance are at increased risk for developing an adductor longus strain.[12]

Rupture or avulsion of the proximal adductor longus is possible; however, most strains occur at or near the myotendinous junction and cause idiopathic groin pain.[12,20] Upon clinical examination, there is weakness and pain with resisted adduction along with decreased abduction ROM.[12,21] Likewise, tenderness to palpation, bruising and

focal swelling around the adductors is usually demonstrated.[12,22] Patients may describe a “pulling” sensation and pain is activity limiting and often causes an antalgic gait pattern.[22] Adductor pain often mimics iliopsoas-related pain or athletic pubalgia. After careful clinical examination, magnetic resonance imaging (MRI) with gadolinium can be helpful in diagnosing an adductor strain or tear.[12,21]

A study by the National Hockey League (NHL) found that adductor strains occur 20 times more often during pre-season play, indicating that decondition may be a large contributor to injury.[21] Preventative strengthening of the hip, pelvis and lower extremities may be key to decreasing the risk of adductor strains. Tyler et al.[23] developed a prevention program that focused on maintaining adductor strength to at least 80% of abductor strength (see table 1). The results of their study show that adductor strengthening (e.g. ball squeezes, concentric adduction, adduction with theraband, seated adduction machine, unilateral lunges, bilateral adduction on sliding board) significantly reduces adductor strain injuries.[23]

The acute treatment of adductor strains should include rest, ice, and NSAIDs to prevent further inflammation.[20,21] Controlled mobilization, including gentle ROM, following the inflammatory phase will be key to preventing atrophy and releasing adhesions.[12,20] Physical therapy should then focus on regaining flexibility, endurance and strength. Finally, an individual may return to sport once 70% of their previous strength has been regained and they have achieved full pain-free range of motion. For an acute strain this process may take up to eight weeks; however for a chronic strain this could take up to six months.[21] Surgical tenotomy is indicated for individuals with

chronic adductor strains that have not responded to treatment after six months of conservative therapy.[21]

Iliopsoas-Related pain:

FAI and acetabular labral tears are both intra-articular causes of anterior hip pain.[1] Adductor strains, athletic pubalgia and iliopsoas bursitis/tendonitis are all considered extra-articular causes.[1] The iliopsoas bursa, also called the iliopectineal bursa, is the largest synovial bursa in the human body (See figure 7).[1] It is positioned between the iliopsoas muscle and the pelvic brim and may even extend to the lesser trochanter.[12] Bursitis occurs as a result of excessive friction from the above iliopsoas tendon causing inflammation within the bursa and often tendonitis to the overlying iliopsoas.[15] The three main causes of iliopsoas bursitis include rheumatoid arthritis, overuse injury, and acute trauma; however for our purposes we will mainly focus on overuse injury.[15] Iliopsoas bursitis is most common in young adults, specifically active young women.[15] It is characterized by anterior groin pain that often radiates down the thigh, and is worsened with the sudden extension of a flexed hip.[15] Unless the bursa is so inflamed that it can be palpated, it will be difficult to clinically differentiate between bursitis and an iliopsoas strain.[22]

Iliopsoas strains are often the result of an overuse injury from repetitive hip flexion (e.g. kicking, running uphill) or from forceful hip flexion against resistance.[22] Iliopsoas strains generally occur at or near the myotendinous junction, but may also occur at the distal insertion into the greater trochanter.[20,22] Patients will often complain of anterior groin pain that radiates into the rectus abdominis and resisted hip flexion will almost always cause pain.[22] Patients will often complain of internal snapping with

associated pain during activity.[1,12] Likewise, there will be tenderness in the femoral triangle with palpation (see figure 8). Clinically, it will be important to assess the extensibility of the iliopsoas muscle using the Thomas Test (see figure 9), with decreased extension or pain with further passive extension by the examiner as indicative of a positive test.[22,24] The Ludloff Test (see figure 10) specifically assesses for iliopsoas strain and thus will be a critical examination component.[22,24] The Ludloff test is performed by positioning a patient in a chair with the involved limb extended and then having them elevate their heel.[22,24] In this position the iliopsoas is the only active hip flexor.[22] A positive test is indicated by sudden deep groin pain.[24] Diagnostic imaging via dynamic ultrasound is often used to confirm the diagnosis of iliopsoas bursitis or iliopsoas strain.[12]

Iliopsoas bursitis and iliopsoas tendonitis are nearly identical in terms of presentation and treatment.[25] Thus, iliopsoas strain and iliopsoas bursitis are often collectively referred to iliopsoas-related pain or iliopsoas syndrome.[12,25] Iliopsoas-related pain is treated very similarly to adductor strains in that initially a period of rest, ice, and NSAID's will be utilized to decrease inflammation.[1,12,20] Quickly thereafter, controlled mobilization followed by stretching and strengthening will be implemented. If bursitis is present, injection of corticosteroids may be needed to decrease inflammation.[26] If conservative measures fail, partial or total iliopsoas tendon release may be indicated.[26]

Conclusion

It is apparent that anterior hip pain can have numerous causes, many of which occur concomitantly. The differential diagnosis of hip and groin pain is extensive and includes many different pathologies.[12] A thorough subjective examination describing the

exact history of the pain followed by detailed objective testing is imperative. The subjective history and the physical examination used in combination with the appropriate diagnostic imaging tools is key to making the correct diagnosis and implementing the most beneficial and effective treatment.[12]

Figures and Tables

Figure 1: FAI-Pincer and Cam Impingement. Pincer lesions show an overgrowth of the acetabular rim. Cam lesions show the asphericity of the femoral head, which disallows it to rotate smoothly within the acetabulum.

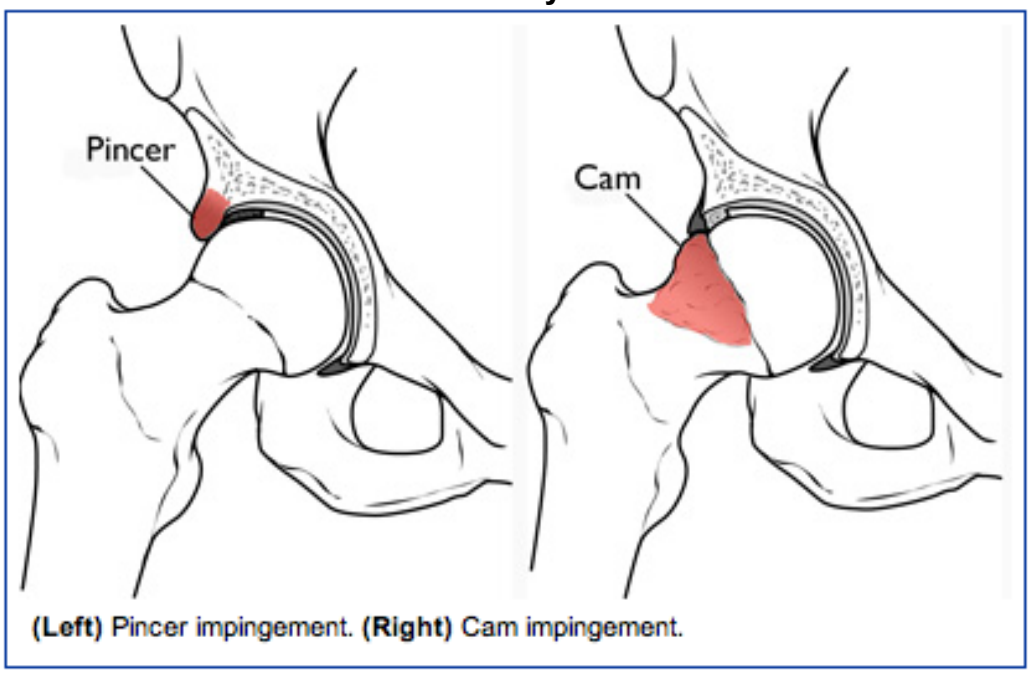

Reference 27. Femoroacetabular impingement (FAI). American Academy of Orthopaedic Surgeons Web site. http://orthoinfo.aaos.org/topic.cfm?topic=A00571. Updated 2010. Accessed December 12, 2012.

Figure 2: The C-Sign is used to identify the location of pain in individuals with FAI

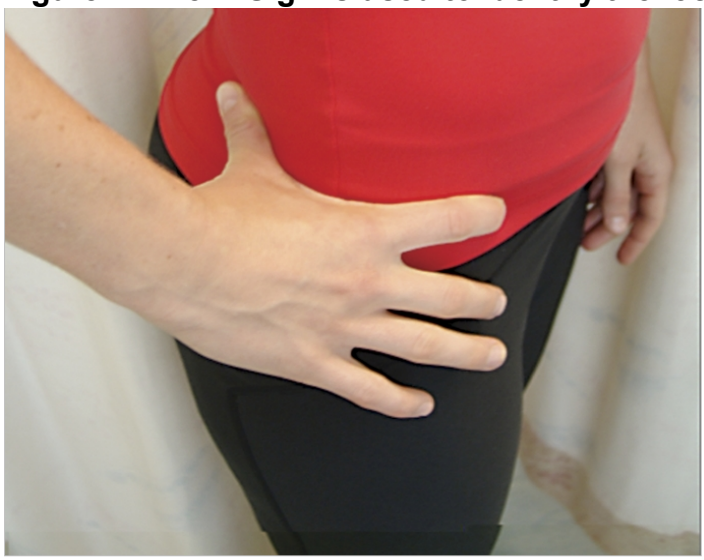

The C sign

The patient indicates location of pain by gripping the affected hip, just above the greater trochanter, between the abducted thumb and index finger.

Reference 6. Dooley PJ. Femoroacetabular impingement syndrome nonarthritic hip pain in young adults. Canadian Family Physician. 2008;54(1):42-47.

Figure 3: Trendelenburg Sign: the contralateral hemipelvis drops during unilateral stance on the involved side due to gluteus medius weakness and adductor insufficiency.

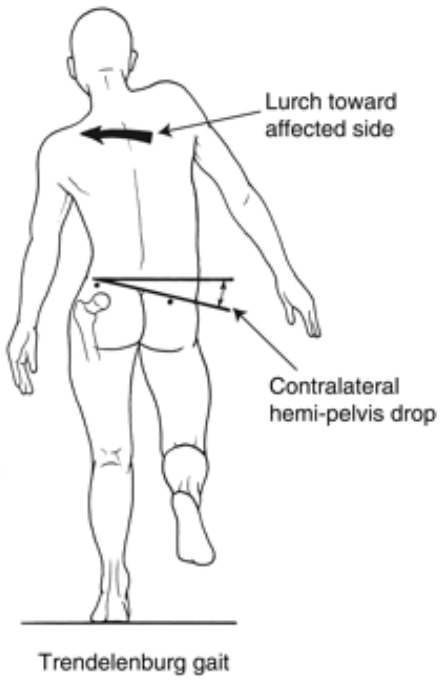

Reference 28. Lim MR, Huang RC, Wu A, Girardi FP, Cammisa FP. Evaluation of the elderly patient with an abnormal gait. *J Am Acad Orthop Surg*. 2007;15(2):107-117.

Figure 4: Impingement Test: Patient in supine position with hip and knee of involved limb flexed to 90˚. The involved leg is adducted and internally rotated. Sudden pain in the groin is a positive test.

Reference 6. Dooley PJ. Femoroacetabular impingement syndrome nonarthritic hip pain in young adults. Canadian Family Physician. 2008;54(1):42-47.

Figure 5: Drehmann Sign. Used to diagnose FAI- compulsory hip abduction and external rotation with hip flexion.

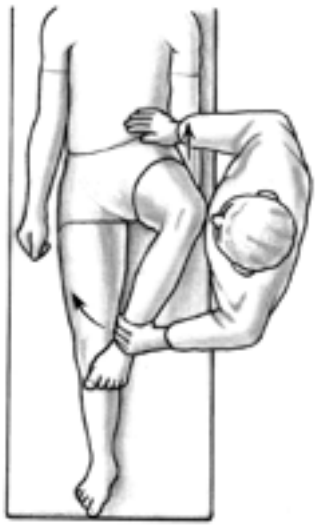

Reference 29. Tannast M, Siebenrock KA, Anderson SE. Femoroacetabular impingement: Radiographic diagnosis—what the radiologist should know. Am J Roentgenol. 2007;188(6):1540-1552.

Figure 6: Fitzgerald test for the anterior labrum



Fitzgerald test for anterior labrum: **A.** Start position: Flexion-external rotation-abduction. **B.** End position: Extension-internal rotation-adduction (Posterior labral test, extension-abduction-external rotation from flexion-adduction-internal rotation not depicted).

Reference 30. Leibold MR, Huijbregts PA, Jensen R. Concurrent criterion-related validity of physical examination tests for hip labral lesions: A systematic review. The Journal of manual & manipulative therapy. 2008;16(2).

Table 1: Tyler's Adductor Strain Protocol

TABLE 1
Adductor Muscle Strain Injury Prevention Program

Warm-up
Bike
Adductor muscle stretching
Sumo squats
Side lunges
Kneeling pelvic tilts
Strengthening program
Ball squeezes (legs bent to legs straight)
Different ball sizes
Concentric adduction with weight against gravity
Adduction while standing with a cable column or elastic resistance
Seated adduction machine
Standing with involved foot on sliding board and moving in the sagittal plane
Bilateral adduction on sliding board and moving in the frontal plane (that is, bilateral adduction simultaneously)
Unilateral lunges with reciprocal arm movements
Sports-specific training
On ice kneeling adductor pull togethers
Standing resisted stride lengths with a cable column to simulate skating
Slide skating
Cable column crossover pulls
Clinical Goal: Adduction strength at least 80% of the adduction strength

Reference 23. Tyler TF, Nicholas SJ, Campbell RJ, Donellan S, McHugh MP. The effectiveness of a preseason exercise program to prevent adductor muscle strains in professional ice hockey players. Am J Sports Med. 2002;30(5):680-683.

Figure 7: Iliopsoas Bursitis

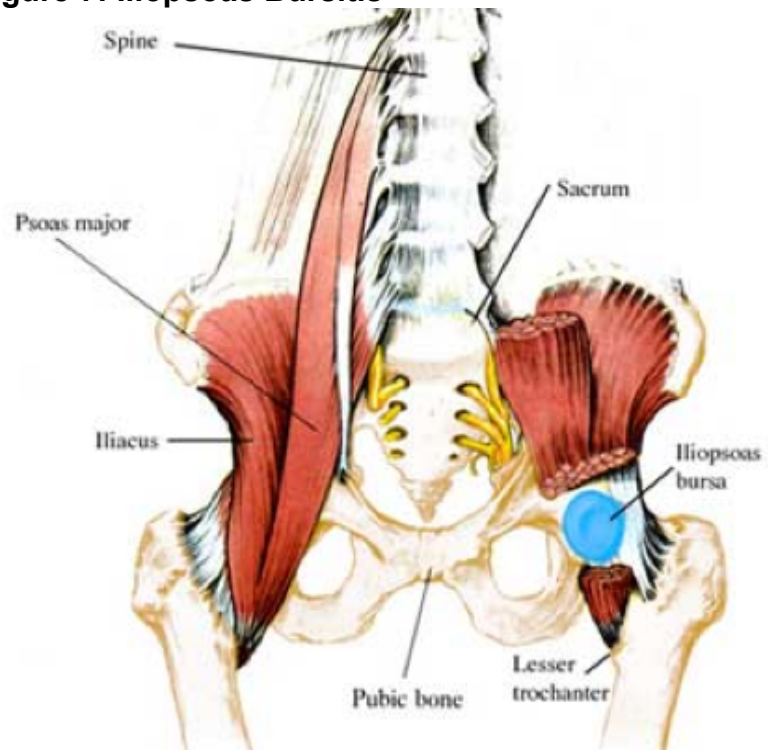

Reference 31. Iliopsoas-bursa. Crossfit Southbay Web site. http://www.crossfitsouthbay.com/2012/11/learn-yourself-lesson-bursa/iliopsoas-bursa/. Updated 2012. Accessed December 3, 2012.

Figure 8: Femoral Triangle- Area for palpating iliopsoas muscle

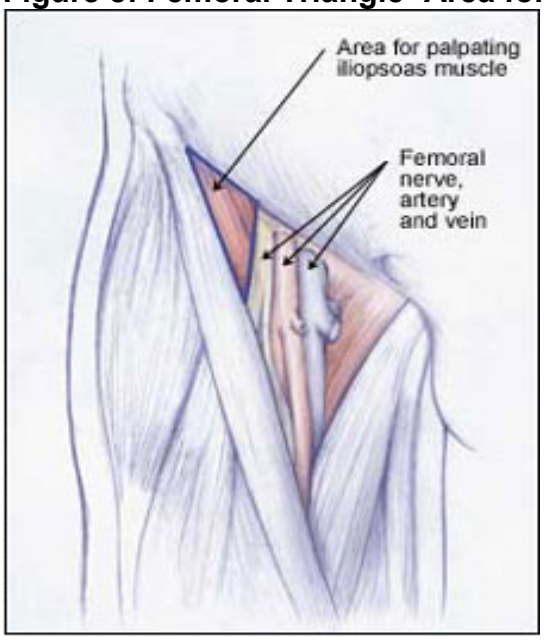

Reference 22. Morelli V, Weaver V. Groin injuries and groin pain in athletes: Part 1. Primary Care-Clinics in Office Practice. 2005;32(1):163-184.

Figure 9: Thomas Test to assess the extensibility of the iliopsoas

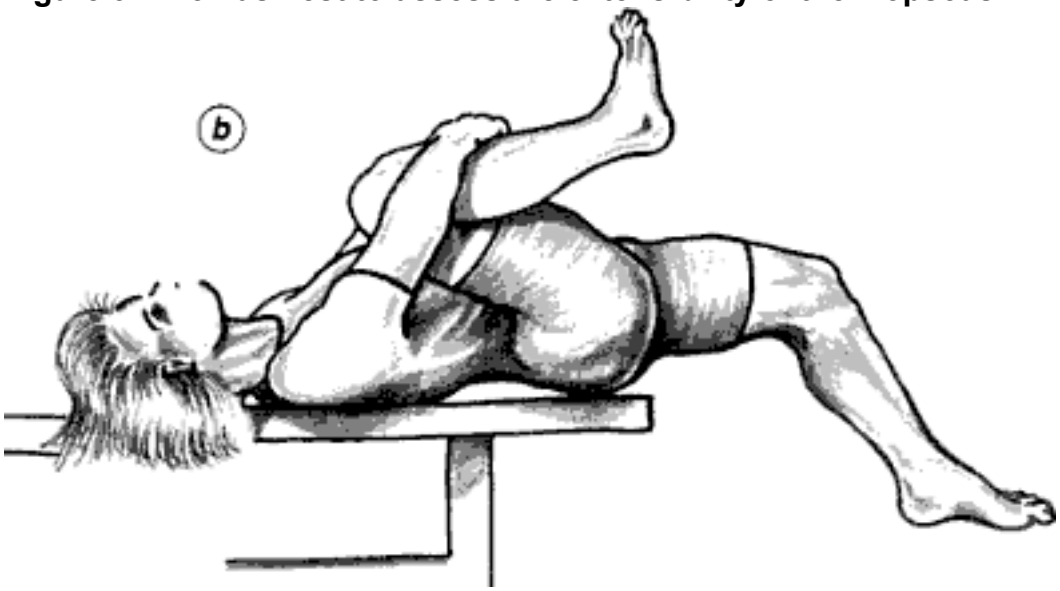

Reference 24. Bahr R, Mæhlum S. Clinical guide to sports injuries. Human Kinetics Publishers; 2004.

Figure 10: Ludloff Test for iliopsoas strain.

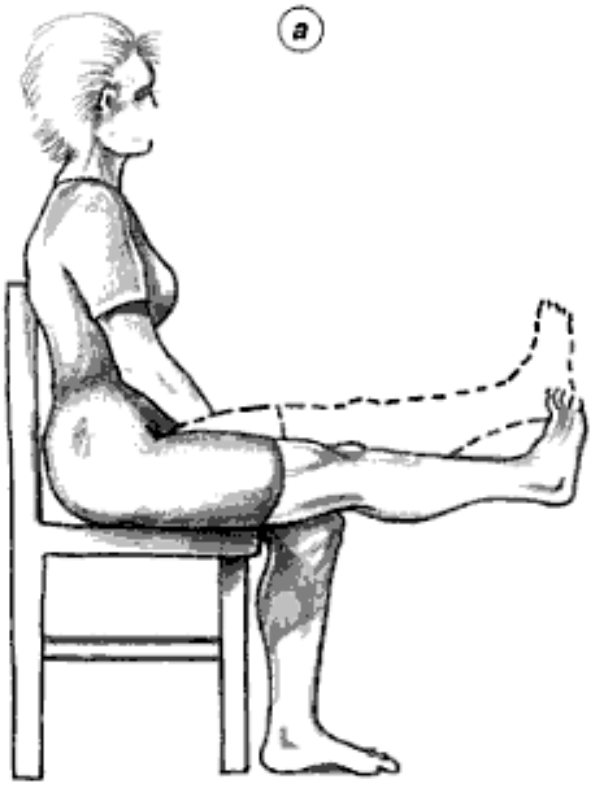

Reference 24. Bahr R, Mæhlum S. Clinical guide to sports injuries. Human Kinetics Publishers; 2004.

References:

1. Flannery O, Green C, Harmon D, Masterson E. Chronic painful conditions of the hip. *Orthopaedics and Trauma*. 2011;25(3):223-229.
2. O'kane JW. Anterior hip pain. *Am Fam Physician*. 1999;60(6):1687.
3. Jaberi FM, Parvizi J. Hip pain in young adults: Femoroacetabular impingement. *J Arthroplasty*. 2007;22(7):37-42.
4. Samora JB, Ng VY, Ellis TJ. Femoroacetabular impingement: A common cause of hip pain in young adults. *Clinical Journal of Sport Medicine*. 2011;21(1):51.
5. Clohisy JC, Knaus ER, Hunt DM, Lesher JM, Harris-Hayes M, Prather H. Clinical presentation of patients with symptomatic anterior hip impingement. *Clinical Orthopaedics and Related Research®*. 2009;467(3):638-644.
6. Ganz R, Parvizi J, Beck M, Leunig M, Nötzli H, Siebenrock KA. Femoroacetabular impingement: A cause for osteoarthritis of the hip. *Clin Orthop*. 2003;417:112-120.
7. Anderson LA, Kapron AL, Aoki SK, Peters CL. Coxa profunda: Is the deep acetabulum overcovered? *Clinical Orthopaedics and Related Research®*. 2012:1-8.
8. Dooley PJ. Femoroacetabular impingement syndrome nonarthritic hip pain in young adults. *Canadian Family Physician*. 2008;54(1):42-47.
9. Kubiak-Langer M, Tannast M, Murphy S, Siebenrock K, Langlotz F. Range of motion in anterior femoroacetabular impingement. *Clin Orthop*. 2007;458:117.
10. Kamegaya M, Saisu T, Nakamura J, Murakami R, Segawa Y, Wakou M. Drehmann sign and femoro-acetabular impingement in SCFE. *Journal of Pediatric Orthopaedics*. 2011;31(8):853.
11. Martin RL, Enseki KR, Draovitch P, Trapuzzano T, Philippon MJ. Acetabular labral tears of the hip: Examination and diagnostic challenges. *J Orthop Sports Phys Ther*. 2006;36(7):503.
12. Tibor LM, Sekiya JK. Differential diagnosis of pain around the hip joint. *Arthroscopy: The Journal of Arthroscopic & Related Surgery*. 2008;24(12):1407-1421.
13. Burgess RM, Rushton A, Wright C, Daborn C. The validity and accuracy of clinical diagnostic tests used to detect labral pathology of the hip: A systematic review. *Man Ther*. 2011;16(4):318-326.
14. Lewis CL, Sahrmann SA. Acetabular labral tears. *Phys Ther*. 2006;86(1):110-121.
15. Farber AJ, Wilckens JH. Sports hernia: Diagnosis and therapeutic approach. *J Am Acad Orthop Surg*. 2007;15(8):507-514.
16. Ahumada LA, Ashruf S, Espinosa-de-los-Monteros A, et al. Athletic pubalgia: Definition and surgical treatment. *Ann Plast Surg*. 2005;55(4):393-396.
17. Lovell G. The diagnosis of chronic groin pain in athletes: A review of 189 cases. *Aust J Sci Med Sport*. 1995;27(3):76.
18. Davis A. Chronic groin pain: Sports hernia. www.theacc.com Web site. http://www.theacc.com/sports/c-track/spec-rel/061005aad.html. Updated 2005. Accessed November 30, 2012.

19. Adductor longus. www.sportsinjuryclinic.net Web site. http://www.sportsinjuryclinic.net/anatomy/human-muscles/hip-pelvis/adductor-longus. Updated 2012. Accessed November 29, 2012.
20. Gross M. Myotendinous Junction and Muscle [PowerPoint slides and Voicethread]. University of North Carolina at Chapel Hill. Advanced Orthopaedic Assessment and Treatment Course.
21. Morelli V, Weaver V. Groin injuries and groin pain in athletes: Part 1. *Primary Care-Clinics in Office Practice*. 2005;32(1):163-184.
22. Hölmich P. Adductor-related groin pain in athletes. *Sports Medicine and Arthroscopy Review*. 1997;5:285-291.
23. Tyler TF, Nicholas SJ, Campbell RJ, Donellan S, McHugh MP. The effectiveness of a preseason exercise program to prevent adductor muscle strains in professional ice hockey players. *Am J Sports Med*. 2002;30(5):680-683.
24. Bahr R, Mæhlum S. *Clinical guide to sports injuries.* Human Kinetics Publishers; 2004.
25. Johnston CAM, Wiley JP, Lindsay DM, Wiseman DA. Iliopsoas bursitis and tendinitis: A review. *Sports Medicine*. 1998;25(4):271-283.
26. Kozlov DB, Sonin AH. Iliopsoas bursitis: Diagnosis by MRI. *J Comput Assist Tomogr*. 1998;22(4):625-628.
27. Femoroacetabular impingement (FAI). American Academy of Orthopaedic Surgeons Web site. http://orthoinfo.aaos.org/topic.cfm?topic=A00571. Updated 2010. Accessed December 12, 2012.
28. Lim MR, Huang RC, Wu A, Girardi FP, Cammisa FP. Evaluation of the elderly patient with an abnormal gait. *J Am Acad Orthop Surg*. 2007;15(2):107-117.
29. Tannast M, Siebenrock KA, Anderson SE. Femoroacetabular impingement: Radiographic diagnosis—what the radiologist should know. *Am J Roentgenol*. 2007;188(6):1540-1552.
30. Leibold MR, Huijbregts PA, Jensen R. Concurrent criterion-related validity of physical examination tests for hip labral lesions: A systematic review. *The Journal of manual & manipulative therapy*. 2008;16(2)
31. Iliopsoas-bursa. Crossfit Southbay Web site. http://www.crossfitsouthbay.com/2012/11/learn-yourself-lesson-bursa/iliopsoas-bursa/. Updated 2012. Accessed December 3, 2012.